

Different manifestations of calcifying cystic odontogenic tumor

Distintas manifestações do tumor odontogênico cístico calcificante

Estevam Rubens Utumi¹, Irineu Gregranin Pedron¹, Leopoldo Penteado Nucci da Silva²,
Gustavo Grothe Machado³, André Caroli Rocha³

ABSTRACT

The calcifying cystic odontogenic tumor normally presents as a painless, slow-growing mass, involving both maxilla and mandible, primarily the anterior segment (incisor/canine area). It generally affects young adults in the third to fourth decades, with no gender predilection. Computerized tomography images revealed important characteristics that were not detected by panoramic radiography, such as fenestration, calcification and tooth-like structures. The typical microscopic feature of this lesion is the presence of variable amounts of aberrant epithelial cells, without nuclei, which are named "ghost cells". In addition, dysplastic dentine can be found and occasionally the cyst can be associated with an area of dental hard tissue formation resembling an odontoma. The treatment for calcifying cystic odontogenic tumor involves simple enucleation and curettage. The purpose of this article is to present two different manifestations of calcifying cystic odontogenic tumor in which computerized tomography, associated to clinical features, served as an important tool for diagnosis, adequate surgical planning and follow-up of patients.

Keywords: Odontogenic cyst, calcifying; Odontogenic tumors; Case reports

RESUMO

O tumor odontogênico cístico calcificante normalmente se manifesta como uma massa indolor, de crescimento lento, que acomete tanto a maxila como a mandíbula, tendo predileção pelo segmento anterior (área dos incisivos e caninos). Geralmente, ocorre em adultos jovens, na terceira a quarta década de vida, sem preferência por gênero. Imagens de tomografia computadorizada revelaram características importantes não detectadas na radiografia panorâmica, tais como fenestração, calcificação e estruturas dentiformes. A característica

microscópica típica dessa lesão é a presença de células epiteliais aberrantes anucleadas, em quantidades variáveis, denominadas "células fantasmas". Também se pode encontrar dentina displásica e, ocasionalmente, os cistos estão associados a tecido dentário duro, semelhante ao odontoma. O tratamento do tumor odontogênico cístico calcificante incluiu simples enucleação e curetagem. O objetivo deste trabalho foi mostrar duas manifestações diferentes do tumor odontogênico cístico calcificante, em que a tomografia computadorizada, associada às características clínicas, foi ferramenta importante para o diagnóstico, o planejamento cirúrgico e o acompanhamento dos pacientes.

Descritores: Cisto odontogênico calcificante; Tumores odontogênicos; Relatos de casos

INTRODUCTION

The calcifying cystic odontogenic tumor (CCOT) is a new designation of calcifying odontogenic cyst (COC) recommended by the 2005 classification of the World Health Organization (WHO). A variety of clinical and histopathologic features was previously described, and several classifications have been proposed⁽¹⁻⁴⁾.

The CCOT normally appears as a painless, slow-growing tumor, involving both maxilla and mandible, primarily the anterior segment (incisor/canine area). It generally affects young adults in the third to fourth decades, without gender predilection⁽⁵⁻⁸⁾.

Radiographically, radiolucent unilocular and, occasionally, multilocular images are seen with well-circumscribed limits containing diffuse opacification

¹ Hospital de Aeronáutica de São Paulo – HASP, São Paulo (SP), Brazil.

² Instituto Israelita de Ensino e Pesquisa Albert Einstein – IIEPAE, Hospital Israelita Albert Einstein – HIAE, São Paulo (SP), Brazil.

³ Hospital das Clínicas, Faculdade de Medicina, Universidade de São Paulo – USP, São Paulo (SP), Brazil.

Corresponding author: Estevam Rubens Utumi – Rua Pelotas, 284 ap 21 – Vila Mariana – Zip code: 04012-902 – São Paulo (SP), Brazil - Phone: (55 11) 5549-8241 - E-mail: estevamutumi@uol.com.br

Received on: Feb 3, 2012 – Accepted on: Aug 3, 2012

areas, associated to impacted or unerupted teeth or other odontogenic tumor^(4,8,9).

Histologically, CCOT is usually composed of a cystic cavity with fibrotic capsule lined by an odontogenic epithelium. The typical microscopic feature of this lesion is the presence of variable amount of aberrant epithelial cells, without nuclei, which are named “ghost cells”. In addition, dysplastic dentine can be found and occasionally the cyst is associated with an area of dental hard tissue formation resembling an odontoma^(4,7,10).

The treatment of CCOT involves simple enucleation with vigorous curettage of the lesion and long term follow-up^(6,11).

The purpose of this article is to report two different manifestations of CCOT, in which computerized tomography (CT) served as an important tool for an adequate planning of surgical removal of the lesion.

CASE 1

A 36 year-old white female was referred to the Oral and Maxillofacial Surgery Department of *Hospital das Clínicas*, São Paulo, Brazil, by her dentist, due to a swollen area in the upper left canine area for 8 months. The patient was asymptomatic, and her medical history was uneventful. The intraoral inspection showed a small vestibular tumefaction at the caninae fossae, as well as the absence of the permanent canine and the first bicuspid teeth. The mucosa aspect was normal (Figure 1).

Periapical radiography showed impacted canine in apparent association with a radiopaque mass and an osteolytic lesion (Figure 2). Panoramic radiography showed displacement of two teeth (canine and first bicuspid) and a radiolucent unilocular lesion partially occupied by a radiopaque mass, resembling an odontoma and involving the left first bicuspid and the canine (Figure 3).

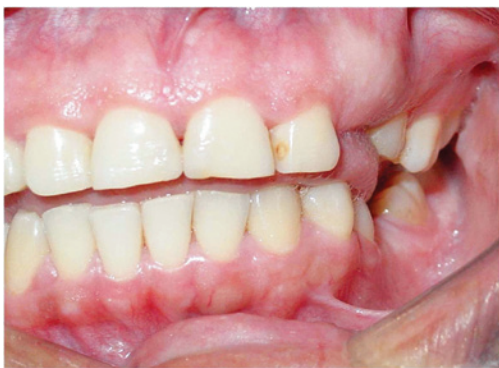

Figure 1. Preoperative intraoral condition showing a vestibular tumefaction at the canine fossae and absence of the permanent canine and first bicuspid

CT was performed for a more complete evaluation. CT images revealed a well-defined circumscribed isodense expanding lesion with thin cortical plate in the left posterior area. Complete opacification of the left sinus was also observed (Figure 4A). Two fragments of radiopaque masses at the distal margin were detected (Figure 4B).

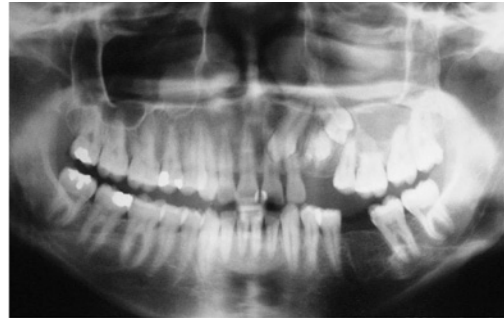

Figure 2. Panoramic radiograph showing displacement of two teeth and a radiopaque mass related to the cystic lesion

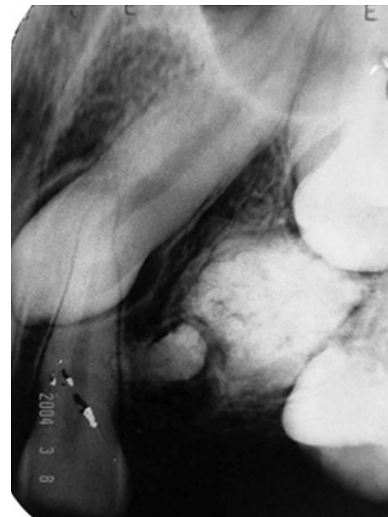


Figure 3. Periapical radiograph of case 1 showing impacted canine and first bicuspid in apparent association with the radiopaque mass in the osteolytic lesion

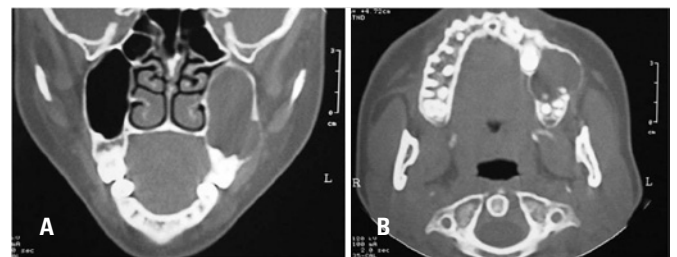


Figure 4. (A) Coronal computed tomography scan showing a large unilocular hypodense image in the left maxillary sinus. The lesion expanded to the maxilla, eroded the lateral sinus wall and spared the nasal cavity. (B) Axial computed tomography scan showing a hypodense lesion associated with buccal and palatal expansion. The small radiopaque portion in the distal part of the lesion, which is not detected on conventional radiographs

The clinical and radiological diagnoses included calcifying odontogenic tumor and odontoma. Aspiration of the lesion presented a brown serous liquid. Surgical enucleation was performed under general anesthesia. An intraoral approach was performed and the lesion was exposed. A thick wall cyst was completely removed, with a dentin-like material and enamel compatible with a compound odontoma inside the cyst. The impacted canine and bicuspid teeth were extracted (Figures 5A and 5B).

Microscopical examination showed a cystic cavity lined by a prominent and well-defined basal layer of cuboidal and luminal cells that focally resembled ameloblastic epithelium with numerous ghost cells and calcified particles. Multiple tooth-like structures were found in the cystic lumen (Figures 6A to 6C). The histopathologic diagnosis was calcifying odontogenic cyst associated with odontoma.

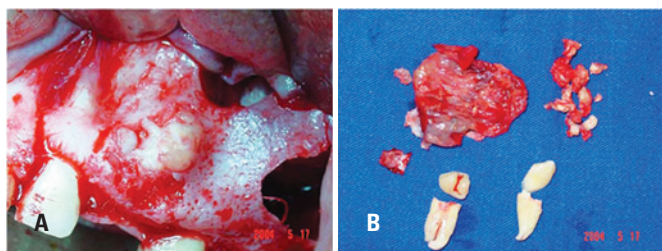


Figure 5. (A) Intraoral surgical aspect showing a calcified lesion as hard as the maxillary bone. (B) Macroscopic view of the surgical resection and extracted impacted canine and first bicuspid teeth

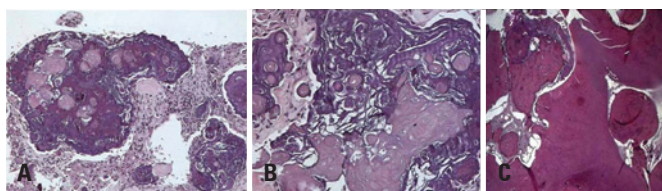


Figure 6. (A) Photomicrograph of the epithelial lining of the calcifying cystic odontogenic tumor displays palisading of the basal layer and masses of "ghost" cells (hematoxylin-eosin, original magnification 50X); (B) innumerable "ghost" cells were observed (hematoxylin-eosin, original magnification 100X); (C) in the cystic lumen, a tooth-like irregular material was found

We reported a normal clinical recovery of the patient after surgery and, after 2 years of follow-up, no recurrence of the lesion was observed.

CASE 2

A 17 year-old male with no relevant medical history was referred to Oral and Maxillofacial Surgery Department of *Hospital das Clínicas*, for an asymptomatic swelling in the mandible. The extraoral examination showed a

right facial swelling and the facial skin was not affected. The intraoral examination showed an expansion in the lower gingivolabial sulcus of right incisors, canine and molars extending to posterior area. The patient was asymptomatic and a normal mucosa was observed in the examination (Figure 7).

Radiographic exams showed a radiolucent, unilocular lesion with well-defined margins and diffuse radiopaque calcifications. No relation with unerupted tooth could be seen (Figure 8). CT images showed a well-circumscribed isodense mass with anteroposterior and lateromedial expansion of the cortices, containing irregular star-shaped opacities in the anterior portion of the mandible (Figure 9).

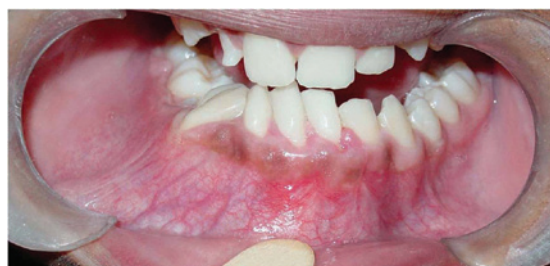

Figure 7. Preoperative intraoral condition showing expansive tumefaction in the anterior region of the mandible causing deviation of the midline

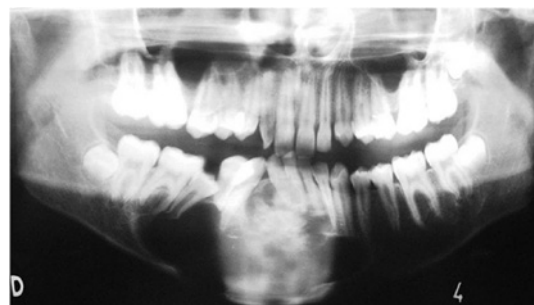


Figure 8. Panoramic radiograph showing large unilocular radiolucent area with calcified material in the anterior region of the mandible

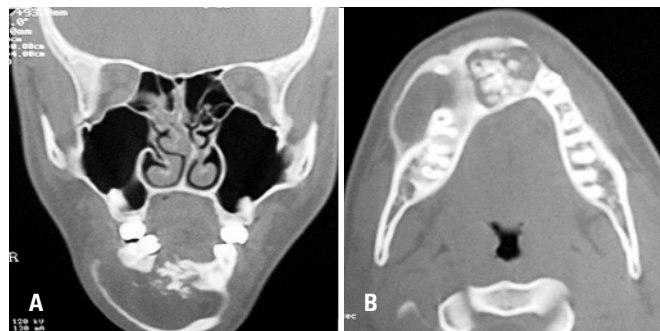

Figure 9. (A) Axial computed tomography scan showing a hypodense lesion associated with calcified deposits inside the lesion. (B) Coronal computed tomography scan showing hypodense lesion and calcified deposits surrounding the alveolar crest

All teeth associated with the lesion showed positive response to vitality tests.

Aspiration of the lesion showed a brown serous liquid content. Incisional biopsy was made under local anesthesia. The histopathologic findings showed a CCOT. Similar findings were seen as in case 1, but no tooth-like components were found.

Total enucleation of the lesion was performed under general anesthesia. Postoperative evolution was satisfactory without complications after 18 months of follow-up. No signs of recurrence were seen.

DISCUSSION

Some authors classified CCOT within the groups of neoplasms and tumors that originate from odontogenic tissues but confirmed that most of the cases were non-neoplastic^(4,12).

CCOTs are usually painless and slow growing tumors^(13,14). When located in the maxilla, patients may sometimes complain of nasal stiffness, epistaxis and headache. Despite of paranasal sinus involvement, the patient described in case 1 did not present any of these symptoms. In case 2, despite the involvement of anterior mandible, the patient was asymptomatic.

The CCOT is rarely associated with other odontogenic tumors, such as ameloblastic fibroma, ameloblastic fibro-odontoma, odontoameloblastoma, or odontogenic myxofibroma^(4,7,15). In the case 1, a rare situation of calcifying odontogenic cyst associated with odontoma was demonstrated. No associated tumors were found in the case 2.

Most cases are intraosseous and radiographically appears as well-defined, unilocular or multilocular radiolucencies with occasional radiopaque deposits of varying sizes and opacities^(8,13,16). In case 2, an unilocular intraosseous lesion with well-defined margins and diffuse radiopaque calcifications was seen.

When calcified material is detected, the possibility of adamantoid tumor, ossifying fibroma, calcifying epithelial odontogenic tumor, and odontoma should be considered^(11,17). In case 1 the lesion revealed an unilocular well-demarcated radiolucency with radiopaque calcified mass involving the left first bicuspid and the canine teeth. The clinical, histological and radiological diagnosis was CCOT with odontoma.

Differential diagnosis of CCOT includes dentigerous cyst, adenomatoid odontogenic tumor, ameloblastic fibro-odontoma, and calcifying epithelial odontogenic tumor. Definitive diagnosis can be made histologically^(4,17).

CT is an important tool for visualization of the internal structure of the lesion and the involvement

of neighboring structures, with high reproducibility of measurements for all dimensions. It has been considered very helpful for clinical diagnosis and treatment planning⁽¹⁸⁾. CCOT generally appear as an unilocular lesion with well-defined margin. Tooth divergence and root resorption were common⁽¹⁹⁾. In both cases reported, CT images revealed important characteristics that were not detected by panoramic radiography, such as fenestration, calcification, and tooth-like structures. Both cases showed a well-defined margin.

We considered CT indispensable for surgical planning. In our cases, CT examination was used to confirm the presence of calcifications along the cyst wall and of tiny flecks that could not be detected by simple radiographic images.

As to histology, both cases were characterized by a well-defined basal layer of cuboidal and luminal cells that focally resembled ameloblastic epithelium with numerous ghost cells and calcified particles. Case 1 was also associated with tooth-like materials (odontoma). Case 2 presented numerous ghost cells and calcified elements but no tooth-like components were found.

There is a wide variety of clinical, radiological, and pathological aspects^(11,18,20). CCOT has been frequently associated with impacted or unerupted teeth or other odontogenic tumor, usually odontomas^(4,7,11,19-21). The most common odontogenic tumor associated to CCOT is odontoma⁽²²⁾. Whether odontomas are frequently associated with CCOT is matter a debate⁽¹⁹⁾. Dentiferous cyst is the second most frequent odontogenic cyst after radicular cyst⁽²²⁾. Our first case demonstrated association with impacted teeth and compound odontoma. Case 2 did not demonstrate similar association.

CCOT treatment depends on the lesion site and histological pattern⁽²²⁾, and includes simple enucleation and curettage, which means enucleation followed by removal of a 1- to 2-mm layer of bone around the periphery of the cystic cavity with a sharp curette or a bone bur. The objective of this procedure is to remove epithelial debris that could originate a recurrent lesion^(11,17). Souza et al.⁽¹¹⁾ reported that marsupialization could be indicated as preliminary treatment to CCOT to minimizing damages in anatomical structures.

Buchner⁽⁶⁾ highlighted the importance of the long term of follow-up. Recurrence is infrequent and malignant behavior is rare⁽⁴⁾.

We emphasize that the choice of treatment should be individualized for each lesion since radiological and histological features may differ from one lesion to another. It could be possible to correlate some characteristics of the macroscopic examination of the surgical specimen and the CT images.

CCOT is a benign odontogenic neoplasm that may manifest occasionally as an aggressive and recurrent tumor^(11,17). In both cases, a conservative treatment was chosen with complete enucleation of the tumor. No recurrence and complications were observed during the follow-up period.

In conclusion, CT scan served an important tool in making an appropriate surgical planning of the lesions in both cases. Definitive diagnosis required pathological examination. Long-term follow-up visits are recommended especially if adjacent structures are also affected.

REFERENCES

1. Toida M. So-called calcifying odontogenic cyst: review and discussion on the terminology and classification. *J Oral Pathol Med*. 1998;27(2):49-52.
2. Hong SP, Ellis GL, Hartman KS. Calcifying odontogenic cyst. A review of ninety-two cases with reevaluation of their nature as cysts or neoplasms, the nature of ghost cells, and subclassification. *Oral Surg Oral Med Oral Pathol*. 1991;72(1):56-64.
3. Li TJ, Yu SF. Clinicopathologic spectrum of the so-called calcifying odontogenic cysts: a study of 21 intraosseous cases with reconsideration of the terminology and classification. *Am J Surg Pathol*. 2003;27(3):372-84.
4. Chindasombataroen J, Kakimoto N, Akiyama H, Kubo K, Murakami S, Furukawa S, et al. Computerized tomography observation of a calcifying cystic odontogenic tumor with an odontoma: case report. *Oral Surg Oral Med Oral Pathol Oral Radiol Endod*. 2007;104(6):e52-7.
5. Yoshida M, Kumamoto H, Ooya K, Mayanagi H. Histopathological and immunohistochemical analysis of calcifying odontogenic cysts. *J Oral Pathol Med*. 2001;30(10):582-8.
6. Buchner A. The central (intraosseous) calcifying odontogenic cyst: an analysis of 215 cases. *J Oral Maxillofac Surg*. 1991;49(4):330-9.
7. Gallana-Alvarez S, Mayorga-Jimenez F, Torres-Gómez FJ, Avellá-Vecino FJ, Salazar-Fernandez C. Calcifying odontogenic cyst associated with complex odontoma: case report and review of the literature. *Med Oral Patol Oral Cir Bucal*. 2005;10(3):243-7.
8. Reyes D, Villanueva J, Espinosa S, Cornejo M. Odontogenic calcific cystic tumor: a report of two clinical cases. *Med Oral Patol Oral Cir Bucal*. 2007;12(2):E126-9.
9. Rushton VE, Horner K. Calcifying odontogenic cyst - a characteristic CT finding. *Br J Oral Maxillofac Surg*. 1997;35(3):196-8.
10. Hirshberg A, Kaplan I, Buchner A. Calcifying odontogenic cyst associated with odontoma: a possible separate entity (odontocalcifying odontogenic cyst). *J Oral Maxillofac Surg*. 1994;52(6):555-8.
11. Souza LN, Souza AC, Gomes CC, Loyola AM, Durigetto AF Jr, Gomez RS, et al. Conservative treatment of calcifying odontogenic cyst: report of 3 cases. *J Oral Maxillofac Surg*. 2007;65(11):2353-6.
12. Krammer IRH, Pindborg JJ, Shear M. World Health Organization classification: histological typing of odontogenic tumours. Berlin: Springer-Verlag, 1993.
13. Gopalakrishnan R, Simonton S, Rohrer MD, Koutlas IG. Cystic variant of calcifying epithelial odontogenic tumor. *Oral Surg Oral Med Oral Pathol Oral Radiol Endo* 2006;102(6):773-7.
14. Anavi Y, Kaplan I, Citir M, Calderon S. Clear-cell variant of calcifying epithelial odontogenic tumor: clinical and radiographic characteristics. *Oral Surg Oral Med Oral Pathol Oral Radiol Endod*. 2003;95(3):332-9.
15. Lin CC, Chen CH, Lin LM, Chen YK, Wright JM, Kessler HP, et al. Calcifying odontogenic cyst with ameloblastic fibroma: report of three cases. *Oral Surg Oral Med Oral Pathol Oral Radiol Endod* 2004;98(4):451-60.
16. Cheng YS, Wright JM, Walstad WR, Finn MD. Calcifying epithelial odontogenic tumor showing microscopic features of potential malignant behavior. *Oral Surg Oral Med Oral Pathol Oral Radiol Endod* 2002;93(3):287-95.
17. Daniels JS. Recurrent calcifying odontogenic cyst involving the maxillary sinus. *Oral Surg Oral Med Oral Pathol Oral Radiol Endod* 2004;98(6):660-4.
18. Cavalcanti MG, Vannier MW. Measurement of the volume of oral tumors by three-dimensional spiral computed tomography. *Dentomaxillofac Radiol*. 2000;29(1):35-40.
19. Uchiyama Y, Akiyama H, Murakami S, Koseki T, Kishino M, Fukuda Y, Shimizutani K, Furukawa S. Calcifying cystic odontogenic tumour: CT imaging. *Br J Radiol*. 2012;85(1013):548-54.
20. Lida S, Fukuda Y, Ueda T, Aikawa T, Arizpe JE, Okura M. Calcifying odontogenic cyst: radiologic findings in 11 cases. *Oral Surg Oral Med Oral Pathol Oral Radiol Endod* 2006;101(3):356-62.
21. Sakai VT, Filho CE, Moretti AB, Pereira AA, Hanemann JA, Duque JA. Conservative surgical treatment of an aggressive calcifying cystic odontogenic maxillary tumor in the young permanent dentition. *Pediatr Dent*. 2011;33(3):261-5.
22. Chindasombataroen J, Poomsawat S, Klongnoi B. Calcifying cystic odontogenic tumor associated with other lesions: case report with cone-beam computed tomography findings. *Oral Surg Oral Med Oral Pathol Oral Radiol*. 2012;113(3):414-20.