

# Morphological, metabolic and functional repercussions after orchietomy in rats

Repercussões morfológicas, metabólicas e funcionais após orquiectomia em ratos

Denny Fabrício Magalhães Veloso<sup>1</sup>, Luiz Ronaldo Alberti<sup>2</sup>, Juliano Alves Figueiredo<sup>3</sup>,  
Fernando Henrique Oliveira Carmo Rodrigues<sup>4</sup>, Andy Petroianu<sup>5</sup>

## ABSTRACT

**Objective:** To study the modifications in lipid profile, blood glucose and pressure, and morphological aspects of the adrenal gland in animals with hypogonadism secondary to total bilateral epididymectomy and orchietomy. **Methods:** Young and adult male Wistar rats were distributed into the following groups: Group 1 – control, animals submitted only to scrotal incision and suture. Group 2 – animals submitted to total bilateral epididymectomy and orchietomy. After these operations, studies were carried out to analyze possible repercussions of hypogonadism. In Study A, serum levels of free testosterone were measured, along with the body weight and cortical thickness of the adrenal gland of 30 adult rats. In Study B, serum values of glucose, triglycerides, total cholesterol, and HDL, LDL and VLDL fractions were measured in 20 young rats and 10 adult rats. In Study C, pressure of the caudal artery was measured by plethysmography in 24 adult animals. **Results:** Total bilateral epididymectomy and orchietomy reduced serum levels of testosterone regardless of the age of the animal, and apparently does not modify macro- or microscopically the morphology of the adrenal gland. Hypogonadism secondary to total bilateral epididymectomy and orchietomy did not modify the serum values of glucose, total cholesterol, LDL and HDL fractions. However, orchietomy reduced the blood levels of triglycerides and VLDL cholesterol when performed in young rats. Testosterone deficiency was related to smaller weight gain and increased arterial pressure. **Conclusions:** Castration reduces blood levels of triglycerides and VLDL cholesterol in young rats. In adult animals, it increases arterial pressure and is related to smaller weight gain.

**Keywords:** Adrenal glands; Blood pressure; Blood glucose; Lipids; Orchietomy; Rats

## RESUMO

**Objetivo:** Estudar modificações no lipidograma, na glicemia, na pressão arterial e nos aspectos morfológicos da glândula adrenal em animais com hipogonadismo secundário à orquiepididimectomia total bilateral. **Métodos:** Foram utilizados ratos machos Wistar jovens e adultos distribuídos nos seguintes grupos: Grupo 1 – controle, animais submetidos apenas a incisão e sutura escrotal. Grupo 2 – animais submetidos à orquiepididimectomia total bilateral. Após essas operações, foram realizados estudos que analisaram possíveis repercussões do hipogonadismo. No Estudo A, foram medidos os níveis séricos de testosterona livre, o peso corpóreo e a espessura cortical da glândula adrenal de 30 ratos adultos. No Estudo B, os valores séricos de glicose, triglicérides, colesterol total e das frações HDL, LDL e VLDL foram medidos em 20 ratos jovens e 10 adultos. No Estudo C mediu-se a pressão da artéria caudal, por meio de pletismografia de 24 animais adultos. **Resultados:** A orquiepididimectomia total bilateral reduziu os níveis séricos de testosterona nos ratos independentemente da idade do animal e, aparentemente, não altera a morfologia da glândula adrenal, tanto macro quanto microscópica. O hipogonadismo secundário à orquiepididimectomia total bilateral não modificou os valores séricos de glicose, do colesterol total e das frações LDL e HDL. Entretanto, a orquiectomia reduziu os níveis sanguíneos de triglicérides e de colesterol VLDL quando realizada em ratos jovens. A deficiência de testosterona relacionou-se com menor ganho ponderal e aumento da pressão arterial. **Conclusões:** A castração reduz os níveis sanguíneos de triglicérides e de colesterol VLDL em ratos jovens. Em animais adultos, aumenta a pressão arterial e se relaciona a menor ganho ponderal.

**Descritores:** Glândulas supra-renais; Pressão arterial; Glicemia; Lipídeos; Orquiectomia; Ratos

Study carried out at Faculdade de Medicina da Universidade Federal de Minas Gerais – UFMG, Belo Horizonte (MG), Brazil.

<sup>1</sup> Master's degree by Faculdade de Medicina da Universidade Federal de Minas Gerais – UFMG, Belo Horizonte (MG), Brazil.

<sup>2</sup> PhD; MD of the Department of Surgery at Universidade Federal de Minas Gerais – UFMG, Belo Horizonte (MG), Brazil.

<sup>3</sup> Master's degree; MD of the Department of Surgery at Universidade Federal de Minas Gerais – UFMG, Belo Horizonte (MG), Brazil.

<sup>4</sup> MD of the Department of Surgery at Universidade Federal de Minas Gerais – UFMG, Belo Horizonte (MG), Brazil.

<sup>5</sup> PhD; MD of the Department of Surgery at Universidade Federal de Minas Gerais – UFMG, Belo Horizonte (MG), Brazil.

Corresponding author: Denny Fabrício Magalhães Veloso – Rua dos Pampas, 538 – apto. 1103b – Prado – CEP 30410-580 – Belo Horizonte (MG), Brasil – Tel.: 31 3295-0372 – E-mail: dennyfmv@yahoo.com.br

Received on Aug 31, 2008 – Accepted on Feb 16, 2009

## INTRODUCTION

Testicles continually produce testosterone from puberty until the end of life. This production decreases after 40 years of age, and may reach levels below normal and cause the clinical condition known as androgen deficiency in aging males (ADAM). This clinical picture is manifested by mood fluctuations, reduced intellectual activity, a decrease in libido and quality of erections, depression, besides a decrease in muscle mass and strength. Populational aging creates challenges related to cardiovascular disturbances, decreased working capacity, and increased physical dependency. Androgen deficiency may accompany male aging and be a part of this picture. The literature is still controversial as to androgenic hormonal replacement in all men with reduced testosterone<sup>(1-3)</sup>.

Castration reduces serum levels of testosterone, but it is important to point out how the adrenal glands, secondary producers of this hormone, react to hypogonadism and what influence the hypothalamus-hypophysis axis has in the production of testosterone<sup>(3)</sup>. The association between testosterone and measurements of arterial pressure, blood glucose, and plasma lipids has not yet been totally established. Hypogonadism is also considered a risk factor for some diseases, such as osteoporosis, osteopenia, hypertriglyceridemia, obesity and arterial hypertension<sup>(4-6)</sup>.

## OBJECTIVE

To study the modifications in lipid profile, blood glucose, arterial pressure, and morphological aspects of the adrenal gland in animals with hypogonadism secondary to total bilateral epididymectomy and orchietomy.

## METHODS

This project was carried out in observance of the recommendations of the International Norms for Protection of Animals and was approved by the Ethics Committee of Animal Experimentation.

Male Wistar rats (*Rattus norvegicus albinus*) were used, both young (Y), 30-day-old, and mature adults (M), aged three to four months. The animals were allocated in appropriate cages with up to four rats per cage and kept under room temperature conditions with natural lighting, obeying a murine circadian cycle. They were observed daily and had no restrictions on supply of water and feed.

The initial weight of the young rats varied between 55 and 80 g, and of the adults, it was between 250 and 350 g. The animals were randomly distributed into groups, according to the operative procedure

performed. In Group 1, control, the rats were submitted to a simulated operation consisting of opening of the scrotum for exposure and manipulation of the testicles. And in Group 2, they were submitted to total bilateral epididymectomy and orchietomy.

All rats were anesthetized with an association of ketamine hydrochloride, with a dose of 50 mg/kg body weight and xylazine hydrochloride, with a dose of 5 mg/kg of body weight, intramuscularly in the gluteus region. During the entire period of anesthesia, heart and respiratory rate were observed, besides voluntary movement of the rats in order to identify the anesthetic level and possible anesthetic complications.

After the operations, the animals were distributed into the following studies in order to answer the issues that were the objective of this project.

### Study A: morphology of the adrenal gland

Thirty adult rats were distributed into three groups:

- Group 1 (n = 10), control;
- Group 2i (n = 10), orchietomy, rats dead on the 30<sup>th</sup> postoperative day, considered the immediate postoperative period (i);
- Group 2t (n = 10), orchietomy, rats dead after eight months postoperatively, during the period considered the late postoperative period (t).

Animals in Groups 1 and 2l were euthanized eight months after the operations in order to measure the serum levels of free testosterone by competitive assay and to evaluate macro- and micro-morphologies of the adrenal glands.

After the 30 day or eight-month follow-up period was concluded, the rats were anesthetized and weighed. In the morning, median laparotomies were performed by layers, and 5 ml sample of blood from the caudal vein was collected to determine the levels of free testosterone. Next, the adrenal glands were removed very carefully in order not to damage them. The animals were euthanized with deepened anesthesia.

The removed glands were processed for the histological study with hematoxylin-eosin to evaluate the general characteristics of the gland, and to establish the limit between the cortical and medullar layers. The thickness of the cortical layer was measured with the help of a lens with a 1 cm ruler marked in tenths of millimeters coupled to the left eyepiece of the optic microscope magnified 40 times.

During the microscopic examination, the adrenal was divided into four quadrants and in each one, the largest measurement of the cortical layer was considered. These four measurements of each gland were recorded for statistical analysis.

## Study B: assessment of blood glucose and lipid profile

Forty rats, young (Y) and mature (M), were distributed into the following groups:

- Group 1 Y (n = 10), control, young rats;
- Group 1 M (n = 10), control, adult rats;
- Group 2 Y (n = 10), orchiectomy, young rats;
- Group 2 M (n = 10), orchiectomy, adult rats.

Blood was collected from all animals to measure blood glucose, total cholesterol and fractions, as well as triglycerides five months after the operations.

The samples were immediately processed. Values of total cholesterol (TC) and high-density lipoprotein (HDL) fraction were measured, as well as those of the triglycerides (TG), using the colorimetric dry chemistry method in an automated biochemistry analyzer. Values of very low density lipoprotein (VLDL) and low-density lipoprotein (LDL) cholesterol were calculated following the Friedewald formula:  $LDL = CT - HDL - TG/5$  and  $VLDL = TG/5$ . Blood glucose was measured by the colorimetric method (glucose-oxidase), with the same apparatus.

## Study C: mean arterial pressure

Twenty-four adult rats were used, distributed into these groups:

- Group 1 (n = 12), control;
- Group 2 (n = 12), orchiectomy.

Mean arterial pressure was measured in the animals before the operations and during the third post-operative month, in both groups, with the help of a plethysmograph located on the animal's tail.

## Statistical analysis

Measurements of adrenal thickness, body weight, free testosterone, blood glucose, and lipid profile were submitted to the Kolmogorov-Smirnov test to determine the Gaussian distribution of the data, and to Bartlett's test to identify variances. Next, variance analysis (ANOVA) was performed. In the results with a significant difference, post-testing was done with Tukey multiple comparisons in order to define which groups were different. Wilcoxon test analyzed the measurements of mean pre and post-operative arterial pressure values in Group 2. The results of post-operative arterial pressure of Groups 1 and 2 were compared with Mann-Whitney test. The significance level considered corresponded to the value of  $p < 0.05$ .

## RESULTS

All animals were euthanized at the end of the study and the data obtained were grouped as per the stages of the research project.

### Study A: morphology of the adrenal gland

One non-orchiectomized adult animal (Group 1) was excluded from the analysis due to a failure in processing the blood sample for testosterone level determination.

In Group 2i, weight gain was smaller than in the Control Group (Table 1). Rats from Group 2i, sacrificed one month after orchiectomy, displayed the smallest weights among the three groups, but it should be considered that they died at a younger age, and therefore cannot be compared to the other two groups.

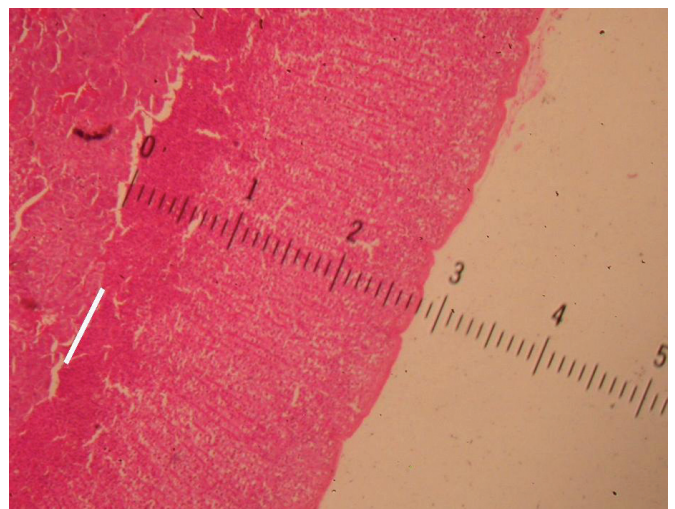
Table 1 shows lower serum levels of testosterone in orchiectomized rats relative to the Control. There was no difference between Groups 2i and 2l ( $p = 0.41$ ).

**Table 1.** Values (mean  $\pm$  mean standard deviation) of body weight, free testosterone and adrenal gland thickness of rats in Groups 1, 2i and 2l

Groups	Weight (g)	Free testosterone (pg/ml)	Adrenal thickness (mm)
Group 1 (n = 9)	546 $\pm$ 37	2,132 $\pm$ 948 **	0.67 $\pm$ 0.06
Group 2i (n = 10)	315 $\pm$ 15	136 $\pm$ 39	0.70 $\pm$ 0.08
Group 2l (n = 10)	452 $\pm$ 21*	87 $\pm$ 14	0.71 $\pm$ 0.06

Group 1 (control): rats dead after 8 months; Group 2 (initial): orchiectomy, rats dead after 30 days; Group 2 (late): orchiectomy, rats dead after 8 months; \* different from mean of Group 1 (control) ( $p < 0.001$ ); \*\* different from mean of other groups ( $p < 0.0001$ )

Orchiectomy did not modify the histological pattern of the medullar and cortical adrenal layers, according to the histological preparation utilized, hematoxylin-eosin. As to the thickness of the adrenal cortex (Figure 1), ANOVA identified no difference between the groups ( $p = 0.54$ ) as seen in Table 1.



**Figure 1.** Thickness of the adrenal cortex measured with a ruler calibrated in millimeters.

### Study B: assessment of blood glucose and lipid profile

Non-orchietomized adult animals were excluded from the analysis (Group 1M) due to a failure in processing the blood samples, leading to hemolysis.

Orchiectomy did not modify serum levels of glucose, total cholesterol, and LDL and HDL fractions ( $p > 0.05$  for all comparisons). However, when performed in young rats, orchiectomy reduced the blood levels of triglycerides and VLDL cholesterol (Table 2).

**Table 2.** Values (mean  $\pm$  mean standard deviation, mg/dl) of blood biochemistry tests of rats collected five months after operations

Groups	Glucose	Cholesterol				Triglycerides
		Total	HDL	LDL	VLDL	
1Y	125 $\pm$ 33	81 $\pm$ 12	25 $\pm$ 4.5	43 $\pm$ 8	12 $\pm$ 3	62 $\pm$ 16
1A	149 $\pm$ 25	77 $\pm$ 10	22 $\pm$ 4.9	42 $\pm$ 6	12 $\pm$ 4	63 $\pm$ 24
2Y	141 $\pm$ 27	86 $\pm$ 15	26 $\pm$ 4.7	51 $\pm$ 10	8 $\pm$ 1.5*	44 $\pm$ 7**
2A	130 $\pm$ 15	79.9 $\pm$ 11	23 $\pm$ 3.7	45 $\pm$ 10	11 $\pm$ 3	57 $\pm$ 15

Group 1Y (young): n = 10, control, young rats; Group 1A (adult): n = 8, control, adult rats; Group 2J (young): n = 10, orchiectomy, young rats; Group 2A (adult): n = 10, orchiectomy, adult rats; \* different from mean as compared to Group 1Y ( $p = 0.005$ ); \*\* different from mean as compared to Group 1Y ( $p = 0.005$ ); HDL: high density lipoprotein; LDL: low density lipoprotein; VLDL: very low density lipoprotein

### Study C: mean arterial pressure

Two animals from Group 2 were excluded due to technical difficulties in blood pressure measurement. These rats did not adapt to the method and were restless in the cage.

The orchietomized animals displayed higher arterial pressures than those in the Control Group. There was a post-operative arterial pressure increase relative to the preoperative period in the rats from Group 2 (Table 3).

**Table 3.** Values (mean  $\pm$  mean standard deviation) of mean blood pressure (mmHg) in the tail of rats in groups 1 and 2

	Preoperative	Post-operative
All rats	104.0 $\pm$ 2.9	
Group 1 (n = 12)		107.8 $\pm$ 3.4*
Group 2 (n = 10)		121.1 $\pm$ 6.4**

Group 1: control and Group 2: orchietomy; \* different from Group 2 ( $p = 0.0348$ ); \*\* different from the preoperative level ( $p = 0.016$ )

## DISCUSSION

Approximately 98% of the circulating testosterone is bound to plasma proteins, 40% is bound to a hepatic glycoprotein called sex hormone binding globulin (SHBG), and 60% is bound to albumin in order to become available when necessary. Biological activity is carried out by the 2% of free testosterone. The enzyme, 5-alpha reductase, present in the testicles, metabolizes testosterone to dihydrotestosterone, which is the active androgen in the tissues<sup>(1)</sup>.

In men, testicular Leydig cells secrete more than 95% of the total circulating testosterone, and the rest is produced by the fasciculate and reticular zones of

the adrenal glands<sup>(7)</sup>. Casquero suggested that after castration in mice, there would not be a sufficient quantity of circulating androgens to carry out the functions of this hormone<sup>(8)</sup>.

In the study of body weight and adrenal gland morphology, eight months after the operations, the Control Group animals had gained more weight than the orchietomized rats. On the other hand, in the study of body weight and arterial pressure, this difference was not present between the groups at the fifth month of follow-up. In the study performed by Vanderschueren et al., castration did not modify body weight<sup>(9)</sup>. Snyder et al. also found no weight changes in men with ADAM submitted to hormone replacement<sup>(10)</sup>. Conversely, Smith et al. noted an increased body weight in patients with prostate cancer who had been castrated<sup>(7)</sup>.

Anti-androgenic therapy may affect the metabolism of glucose mediated by modifications of body composition, especially an accumulation of visceral fat. Smith et al. found hyperinsulinemia with normal blood glucose in men with prostate cancer who had been castrated, similar to diabetic patients with increased insulin resistance<sup>(11)</sup>. The blood glucose of rats in this project was not altered after castration.

Epidemiological data documented the relation between the plasma level of total cholesterol and coronary risk, especially for males under the age of 40 years<sup>(12)</sup>. Increases in total cholesterol and LDL fraction are factors associated with the higher risk of atherosclerosis and coronary disease, while the increase in HDL is a protective factor. It is known that hypercholesterolemia is significant in more than 50% of patients with cardiovascular diseases, even when considering other local inflammatory disturbances that share responsibility for atherogenesis<sup>(13)</sup>.

Cholesterol is the principal substrate for synthesis of testosterone. According to Isidori et al., there is a reduction in total cholesterol after androgenic therapy in men, with no change in the LDL and HDL fractions<sup>(6)</sup>. In the present study, castration of the rats did not modify the serum levels of total cholesterol or of its LDL and HDL fractions.

In addition, in this study, orchietomy in young rats reduced the blood levels of triglycerides and the VLDL cholesterol fraction. Such changes might be indicators of the influence of testosterone on the metabolism of lipids and cholesterol, which still need to be investigated<sup>(12,14)</sup>. There is evidence of the role of hypertriglyceridemia in atherogenesis, and more recently, in the VLDL fraction of cholesterol as well<sup>(15)</sup>.

According to the literature, the reduction in free testosterone may be related to changes in the morphology of the adrenal gland<sup>(16)</sup>. However, in this study, the adrenal cortical thicknesses did not change after orchietomy.

Cherry et al., in animals with hypogonadism, and Parker et al., in individuals who died from trauma, found no difference in the total adrenal cortical thickness after hypogonadism, although they detected a proportional reduction of the reticular zone relative to the other cortical zones<sup>(16,17)</sup>. Since testosterone is produced in the testicles and adrenal glands, it is necessary to clarify if the adrenal gland takes on an endocrine compensatory role after orchietomy.

The invasive method of measuring the arterial pressure in rats requires a continuous infusion of an anticoagulant to maintain blood flow. The pain caused by the arterial puncture may affect the heart rate and arterial pressure. In order to avoid these inconveniences, it was opted for a non-invasive method. Additionally, the accuracy of non-invasive blood pressure measurements does not differ from that of invasive methods in rats with normal pressure levels, as long as the examiner is qualified and the animal is trained, even considering that invasive methods may be better. A calm environment, adequate acclimatization, and gentle handling of the animals diminish intercurrent factors and increase reliability of measurements<sup>(18)</sup>.

A literature review indicates that the administration of testosterone exacerbates the arterial pressure of previously hypertensive rats and that the castration of these animals reduces the arterial pressure<sup>(19,20)</sup>. Nevertheless, the same effect was not documented in rats with normal arterial pressure levels. In this study, castration was accompanied by an increase in blood pressure, a result similar to that found by Calhoun et al.<sup>(21)</sup>.

Within Leydig cells, cholesterol is the precursor of sexual hormones and the main substrate for the synthesis of testosterone. During adolescence, the levels of cholesterol fractions HDL and LDL decrease. The levels of HDL are inversely related to testosterone in pubescent boys. These changes during sexual maturation indicate that the sexual hormones participate in the metabolism of the lipoproteins<sup>(22)</sup>.

Some authors reported an increase in the LDL fraction in situations of testosterone deficiency in different species, including hypogonadal humans<sup>(23)</sup>. The decrease in HDL was observed in studies carried out in hypogonadal men and in castrated mice<sup>(24)</sup>.

On the other hand, an increase or absence of variation of HDL levels also occurred in men with testosterone deficiency, and in castrated monkeys and mice<sup>(23)</sup>.

Some animal studies showed that testosterone possesses a coronary vasodilation action on the thoracic aorta, pulmonary vasculature, and isolated mesenteric veins<sup>(25-28)</sup>. Testosterone not only induces vasodilatation by the release of nitrous oxide, but also clearly acts in

improving sensitivity of smooth vascular muscles to the action of this molecule<sup>(27)</sup>.

## CONCLUSIONS

Total bilateral epididymectomy and orchietomy reduce the serum levels of testosterone in rats, regardless of the animal's age. There are no apparent morphological changes of the adrenal gland, whether macroscopic or microscopic.

Hypogonadism secondary to total bilateral epididymectomy and orchietomy does not change serum values of glucose, total cholesterol, or the LDL and HDL fractions. Nonetheless, castration of young rats reduces the blood levels of triglycerides and of VLDL cholesterol.

Testosterone deficiency is also related to a smaller late weight gain and an increase in blood pressure.

## REFERENCES

- Basaria S, Dobs AS. Hypogonadism and androgen replacement in elderly men. *Am J Med.* 2001;110(7): 563-72.
- Bhasin S, Cunningham GR, Hayes FJ, Matsumoto AM, Snyder PJ, Swerdloff RS, et al. Testosterone therapy in adult men with androgen deficiency syndromes: an endocrine society clinical practice guideline. *J Clin Endocrinol Metab.* 2006;91(6):1995-2010.
- Lopes EJA. Análise da deficiência androgênica e terapia de reposição em homens idosos [tese]. São Paulo: Universidade de São Paulo; 2004.
- Daniell HW, Dunn SR, Ferguson DW, Lomas G, Niazi Z, Stratte PT. Progressive osteoporosis during androgen deprivation therapy for prostate cancer. *J Urol.* 2000;163(1):181-6.
- Ross RW, Small EJ. Osteoporosis in men treated with androgen deprivation therapy for prostate cancer. *J Urol.* 2002;167(5):1952-6.
- Isidori AM, Giannetta E, Greco EA, Gianfrilli D, Bonifacio V, Isidori A, et al. Effects of testosterone on body composition, bone metabolism and serum lipid profile in middle-aged men: a meta-analysis. *Clin Endocrinol (Oxf).* 2005;63(3):280-93.
- Smith MR, Finkelstein JS, McGovern FJ, Zietman AL, Fallon MA, Schoenfeld DA, et al. Changes in body composition during androgen deprivation therapy for prostate cancer. *J Clin Endocrinol Metab.* 2002;87(2): 599-603.
- Casquero AC. Efeitos de hormônios sexuais masculinos sobre o metabolismo das lipoproteínas plasmáticas e expressão da CETP em camundongos geneticamente modificados sedentários e exercitados [tese]. São Paulo: Universidade Estadual de Campinas; 2005.
- Vanderschueren D, Vandenput L, Boonen S, Van Herck E, Swinnen JV, Bouillon R. An aged rat model of partial androgen deficiency: prevention of both loss of bone and lean body mass by low-dose androgen replacement. *Endocrinology.* 2000;141(5):1642-7.
- Snyder PJ, Peachey H, Hannoush P, Berlin JA, Loh L, Lenrow DA, et al. Effect of testosterone treatment on body composition and muscle strength in men over 65 years of age. *J Clin Endocrinol Metab.* 1999;84(8):2647-53.
- Yannucci J, Manola J, Garnick MB, Bhat G, Bublely GJ. The effect of androgen deprivation therapy on fasting serum lipid and glucose parameters. *J Urol.* 2006;176(2):520-5.
- Hak AE, Witteman JC, de Jong FH, Geerlings MI, Hofman A, Pols HA. Low levels of endogenous androgens increase the risk of atherosclerosis in

- elderly men: the Rotterdam study. *J Clin Endocrinol Metab.* 2002;87(8):3632-9.
13. Hansson GK. Immune mechanisms in atherosclerosis. *Arterioscler Thromb Vasc Biol.* 2001;21(12):1876-90.
  14. Weidemann W, Hanke H. Cardiovascular effects of androgens. *Cardiovasc Drug Rev.* 2002;20(3):175-98.
  15. Ballantyne CM, Grundy SM, Oberman A, Kreisberg RA, Havel RJ, Frost PH, et al. Hyperlipidemia: diagnostic and therapeutic perspectives. *J Clin Endocrinol Metab.* 2000;85(6):2089-112.
  16. Parker CR Jr, Mixon RL, Brissie RM, Grizzle WE. Aging alters zonation in the adrenal cortex of men. *J Clin Endocrinol Metab.* 1997;82(11):3898-901.
  17. Cherry BA, Cadigan B, Mansourian N, Nelson C, Bradley EL. Adrenal gland differences associated with puberty and reproductive inhibition in *Peromyscus maniculatus*. *Gen Comp Endocrinol.* 2002;129(2):104-13.
  18. Whitesall SE, Hoff JB, Vollmer AP, D'Alecy LG. Comparison of simultaneous measurement of mouse systolic arterial blood pressure by radiotelemetry and tail-cuff methods. *Am J Physiol Heart Circ Physiol.* 2004;286(6):H2408-15.
  19. Martin DS, Bilofto S, Redetzke R, Vogel E. Castration reduces blood pressure and autonomic venous tone in male spontaneously hypertensive rats. *J Hypertens.* 2005;23(12):2229-36.
  20. Reckelhoff JF. Sex steroids, cardiovascular disease, and hypertension: unanswered questions and some speculations. *Hypertension.* 2005;45(2):170-4.
  21. Calhoun DA, Zhu ST, Chen YF, Oparil S. Gender and dietary NaCl in spontaneously hypertensive and Wistar-Kyoto rats. *Hypertension.* 1995;26(2):285-9.
  22. Morrison JA, Barton BA, Biro FM, Sprecher DL. Sex hormones and the changes in adolescent male lipids: longitudinal studies in a biracial cohort. *J Pediatr.* 2003;142(6):637-42.
  23. Alexandersen P, Christiansen C. The aging male: testosterone deficiency and testosterone replacement. An up-date. *Atherosclerosis.* 2004;173(2):157-69.
  24. Tan KC, Shiu SW, Pang RW, Kung AW. Effects of testosterone replacement on HDL subfractions and apolipoprotein A-I containing lipoproteins. *Clin Endocrinol (Oxf).* 1998;48(2):187-94.
  25. Deenadayalu VP, White RE, Stallone JN, Gao X, Garcia AJ. Testosterone relaxes coronary arteries by opening the large-conductance, calcium activated potassium channel. *Am J Physiol Heart Circ Physiol.* 2001;281(4):H1720-7.
  26. Ding AQ, Stallone JN. Testosterone-induced relaxation of rat aorta is androgen structure specific and involves K<sup>+</sup> channel activation. *J Appl Physiol.* 2001;91(6):2742-50.
  27. Jones RD, Pugh PJ, Jones TH, Channer KS. The vasodilatory action of testosterone: a potassium-channel opening or a calcium antagonistic action? *Br J Pharmacol.* 2003;138(5):733-44.
  28. Tep-areenan P, Kendall DA, Randall MD. Testosterone-induced vasorelaxation in the rat mesenteric arterial bed is mediated predominantly via potassium channels. *Br J Pharmacol.* 2002;135(3):735-40.
  29. Smith JC, Bennett S, Evans LM, Kynaston HG, Parmar M, Mason MD, et al. The effects of induced hypogonadism on arterial stiffness, body composition and metabolic parameters in males with prostate cancer. *J Clin Endocrinol Metab.* 2001;86(9):4261-7.